

# FEDERATION CYNOLOGIQUE INTERNATIONALE (AISBL)

13, Place Albert 1er, B - 6530 Thuin (Belgique), tel : ++32.71.59.12.38, website : <https://www.fci.be>

---



## FCI HIP DYSPLASIA CLASSIFICATION

This classification has been made up on account of the radiological features only and is as objective as possible. Minor variances from the criteria listed in the definitions of the hip dysplasia (HD) grades are possible as anatomic variation can occur between and within breeds.

### Attachment

Guidelines, how to measure Norberg Angle.

## **GRADE A**

The femoral head is well centred in the acetabulum and the joint space is narrow and even. The subchondral bone of the femoral head and the cranial acetabular margin are parallel or almost parallel, with the exception of the fovea capitis.

The subchondral bone plate of the cranial acetabular margin is a fine line of even thickness; in excellent hip joints the subchondral bone can end before the craniolateral rim.

The craniolateral rim should be well defined and rounded, parallel to the femoral head; in excellent hips the craniolateral rim encircles the femoral head in caudolateral direction.

The centre of the femoral head is medial to the dorsal margin of the acetabulum.

The Norberg angle is about 105° (as a reference).

No signs of osteoarthritic changes are present.

## **GRADE B**

The femoral head is centred in the acetabulum and the joint space is narrow, however the subchondral bone of the femoral head and the cranial acetabular margin can be diverging i.e., not parallel.

The subchondral bone plate of the cranial acetabular margin is a fine line with even thickness.

At the lateral part, the craniolateral rim is horizontal, i.e., after its maximum in a straight line in the transverse plane.

The centre of the femoral head is medial or superimposed to the dorsal margin of the acetabulum.

The Norberg angle is at least 100° (as a reference).

No signs of osteoarthritic changes are present.

## **GRADE C**

The femoral head is not centred well in the acetabulum and the subchondral bone of the femoral head and cranial acetabular margin are diverging i.e., not parallel.

The subchondral bone plate of the cranial acetabular margin can be slightly thickened laterally and/or slightly reduced medially.

The craniolateral rim can be slightly flattened, i.e., the craniolateral margin diverges from the femoral head in a craniolateral direction.

The centre of the femoral head is superimposed or lateral to the dorsal margin of the acetabulum.

Subluxation of the femoral head, lateral or caudal, can be present.

The Norberg angle is about 100° (as a reference).

Signs of osteoarthritic changes can be present.

## **GRADE D**

The femoral head is not centred well in the acetabulum and the subchondral bone of the femoral head and the cranial acetabular margin are obviously diverging.

The subchondral bone plate of the cranial acetabular margin is moderately thickened laterally and/or moderately reduced medially

The craniolateral rim is markedly flattened i.e., the craniolateral margin leaves the femoral head in a craniolateral direction.

The centre of the femoral head is lateral to the dorsal margin of the acetabulum.

Subluxation of the femoral head, lateral or caudal, can be present.

The Norberg angle is more than 90° (as a reference).

Signs of osteoarthritic changes can be present.

## GRADE E

Marked dysplastic changes of the hip joint. Remodelling and deformation of the acetabulum and/or the femoral head may be present.

The subchondral bone of the femoral head and the subchondral bone plate of the cranial acetabular margin are obviously diverging with obvious flattening.

The cranial acetabular margin is markedly thickened laterally blending with the craniolateral rim. Thickening of the cranial acetabular margin can be absent in luxated hip joints.

The craniolateral rim is markedly flattened i.e., the craniolateral margin leaves the femoral head in a craniolateral direction. The craniolateral rim may be absent.

The centre of the femoral head is lateral to the dorsal margin of the acetabulum.

Luxation or subluxation of the femoral head.

The Norberg angle is less than 90° (as a reference).

Signs of osteoarthritic changes can be present.

## ANNEX - Guidelines, how to measure the Norberg Angle

1 Use hip radiographs in position 1, with the correctly pronated femora with the patellae centred in the femoral condyles, with femora parallel to each other and parallel to the spine. The pelvis must be symmetric without any right or left rotation in the long axis, parallel as much as possible to the table and without rotation in the short axis.

2 Define the center of each femoral head by using a transparent sheet of plastic with concentric rings engraved with the following angles depicted as radius: 80°, 90°, 100°, and 105°, or using computer software. The center of the femoral head is defined by the arc of the cranial and medial circular sectors respectively.

3 Localize the intersection between the cranial and the dorsal acetabular margins which is called the cranial effective acetabular rim.

4 The Norberg angle (NA) is formed by a line connecting the cranial effective acetabular rim and the center of the femoral head and the line connecting the centers of the femoral heads.

5 The NA is registered for each hip individually.

## Examples

Figure 1

Normal hip joint. The cranial and dorsal contour of the acetabulum meet at the cranial effective acetabular rim. The fine and even subchondral bone plate (almost) reaches the craniolateral acetabular rim. Reference point for the NA measurement is the cranial effective acetabular rim.

This measuring point is at the lateral end of the weight bearing area of the acetabulum which is still in contact with the femoral head. Depending on the quality of the radiograph this point is indicated by the lateral end of the subchondral bone opacity. Under- and over rotation of the pelvis makes identification of this point more difficult (see Fig 3).

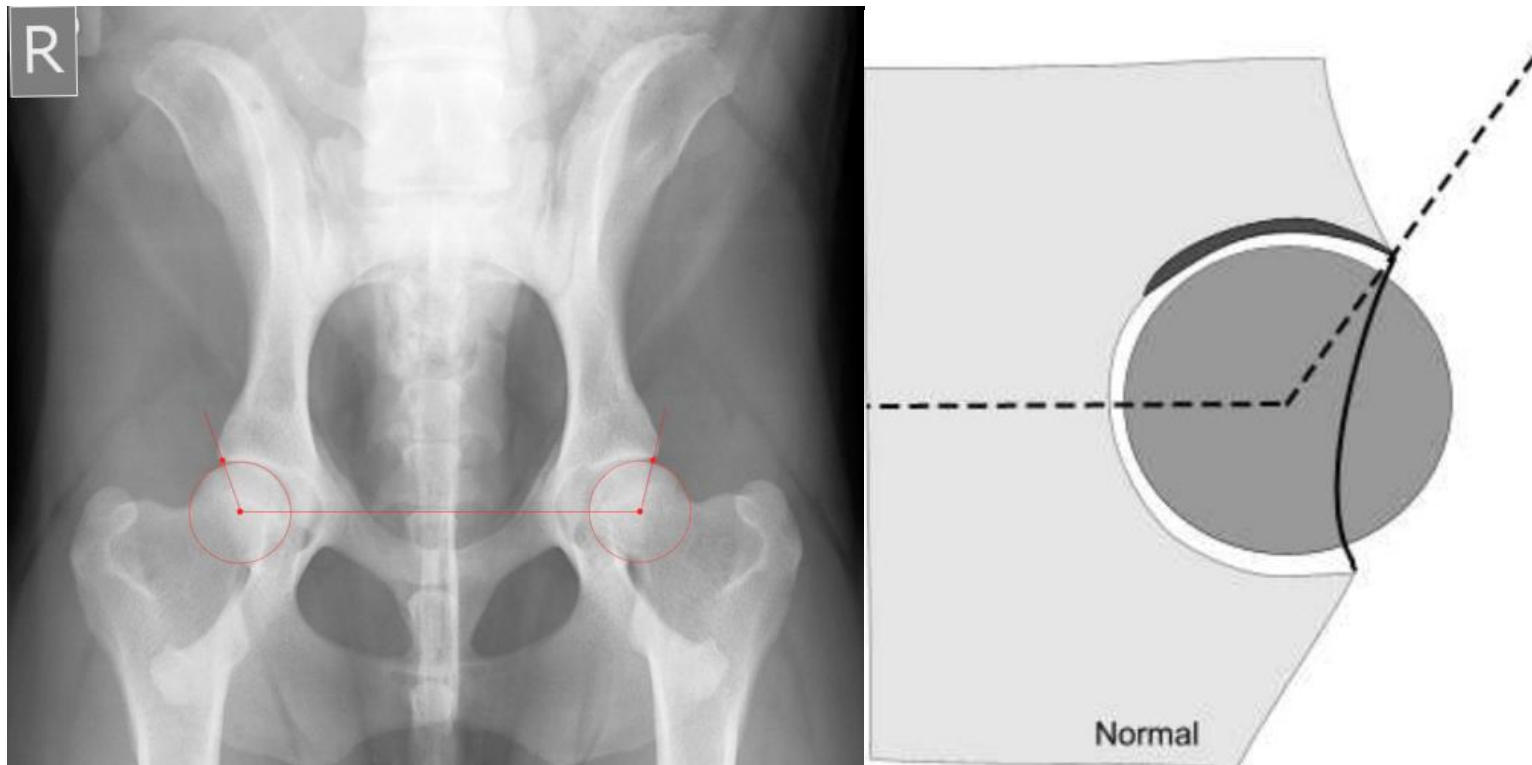
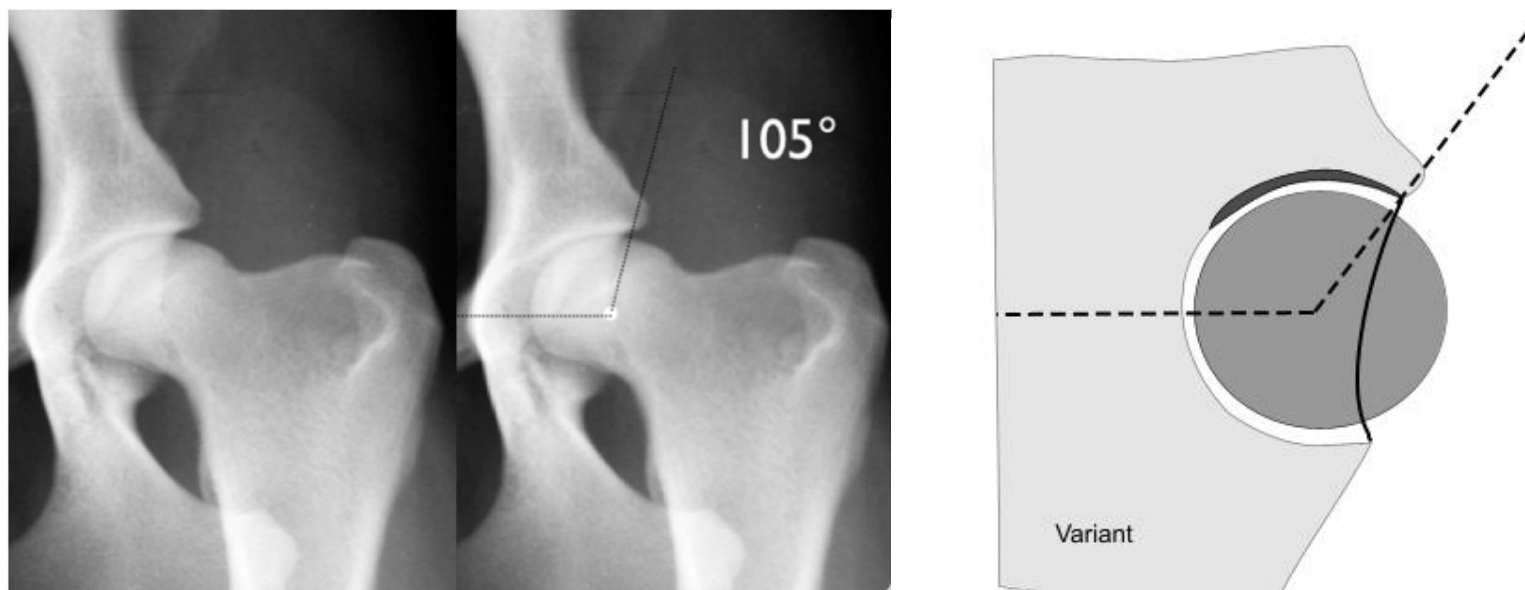




Figure 2



Anatomical variation of a normal hip joint with the os ilium forming a protuberance. Reference point for the NA measurement is located medial to the protuberance, at the lateral end of the subchondral bone plate.

Figure 3

Over rotation of the pelvis along its short axis, reflected by the almond shaped obturator foramen. The intersection between cranial and dorsal acetabular margin is projected further medial. The subchondral bone plate reaches further lateral.

Reference point for NA measurement: lateral border of the subchondral bone plate.

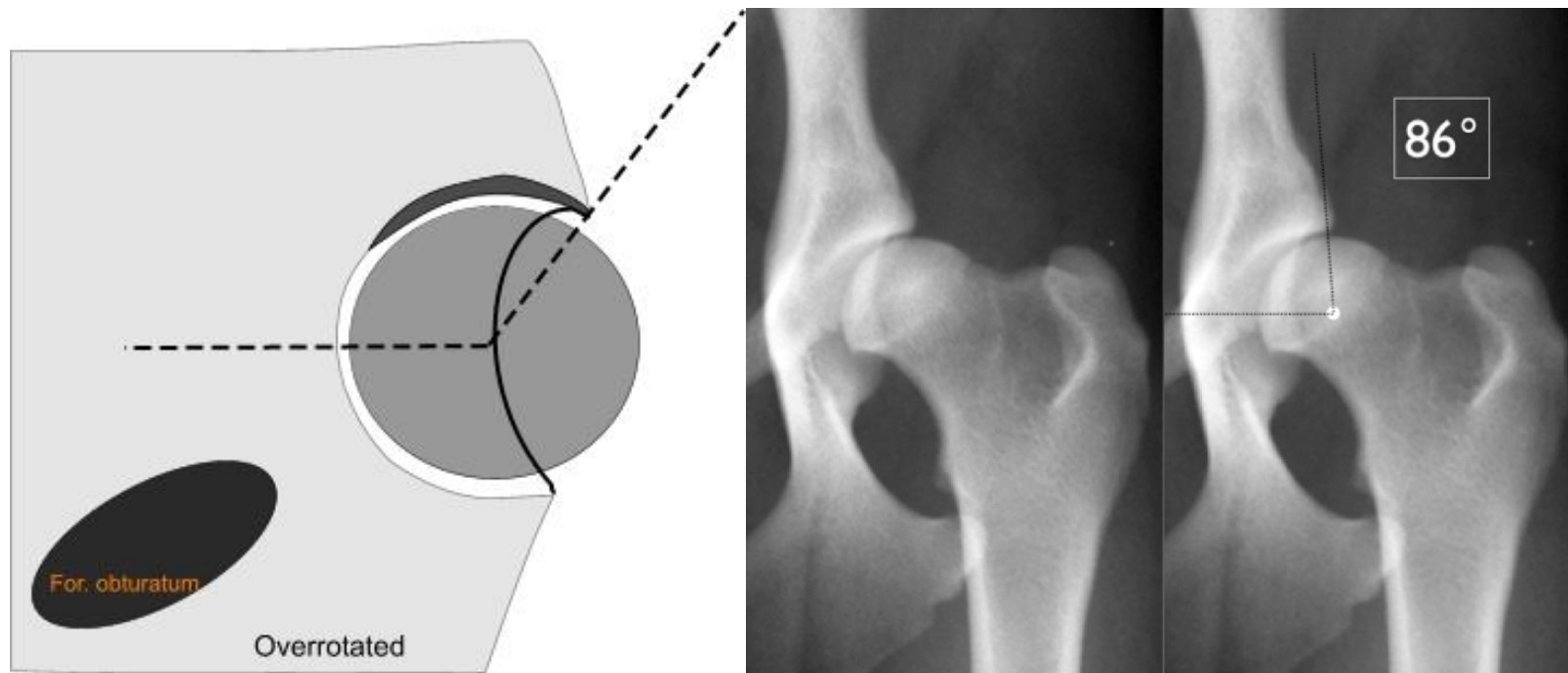
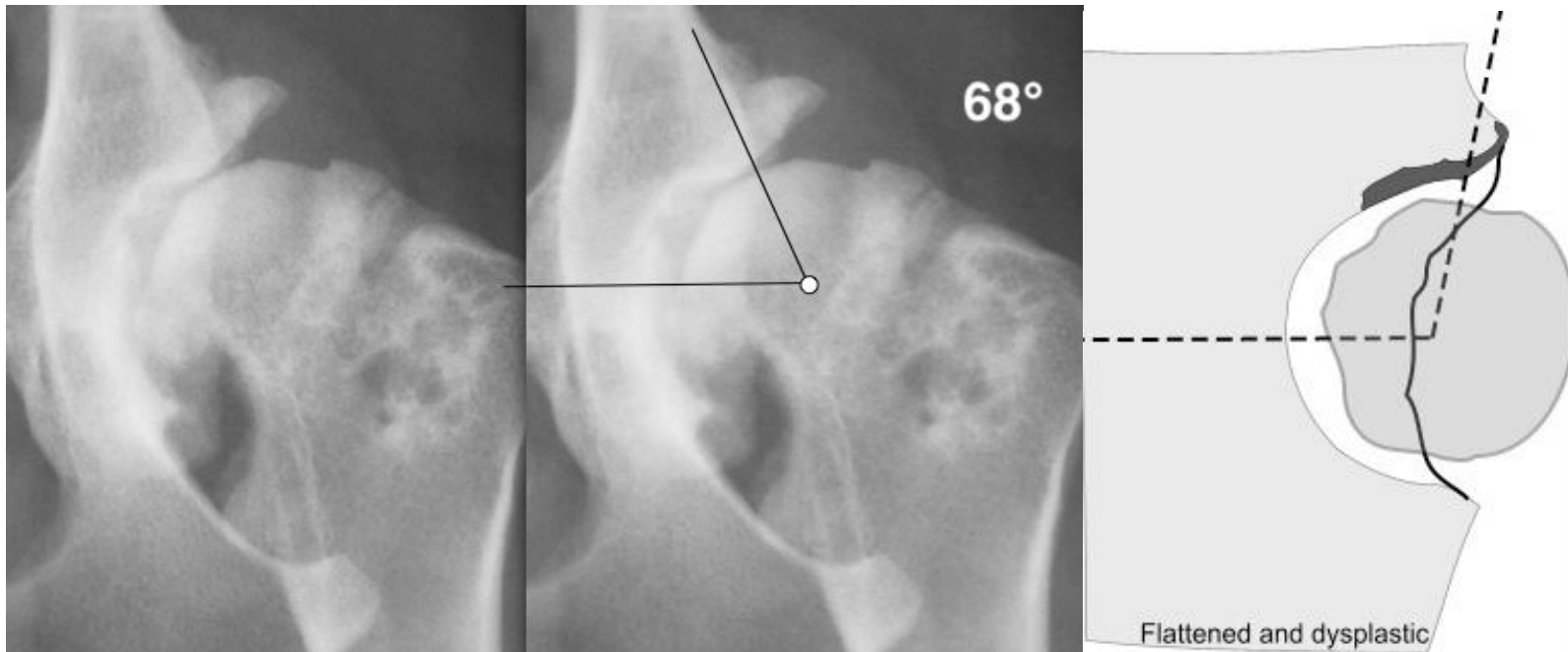


Figure 4



Dysplastic hip joint with a flattened craniolateral acetabular rim and an irregular and broad subchondral bone plate. The reference point for the NA measurement is set at the end of the weight bearing zone, where the cranial acetabular contour deviates.

**This document was prepared by Hip Dysplasia panellists on the occasion of FCI/DKK Hip Dysplasia Conference in Copenhagen, May 24 and 25, 2022 and approved by the FCI Scientific Commission and the FCI General Committee on the occasion of its meeting in Madrid, November 22-23 2022.**